

## ● **Marek's Disease (MD)**

- MD is a highly contagious viral neoplastic disease of chickens that is characterized by varying degrees of paralysis of the wings and legs and the presence of lymphoid tumors in various organs.
- Marek's disease (MD) virus may attack the nervous system and results in enlarged nerves result in paralysis or it may attack the visceral system and cause tumors in the internal organs , muscle and epithelial (cells that line the internal and external surfaces of the body) tissue.
- Poultry may be unable to lay eggs or may even die. Young birds are more susceptible than older birds with death most common between the ages of 8 and 20 weeks.



## Etiology

### Group B Herpes Virus

It is caused by a cell-associated Herpes virus containing double-stranded DNA. It has hexagonal naked particles or nucleocapsids of 85 or 100 nm. Enveloped particles of 150-400 nm are occasionally seen in the feather follicle epithelium.

There are 3 serotypes.

- Serotype 1 viruses can be oncogenic (causes tumors to chickens )e.g.(CV1 988).
- Serotype 2 virus non oncogenic type from chickens, e.g. (SB1).
- - serotype 3 (herpes virus of turkeys -HVT), do not cause tumors and are used as vaccines.
- One attenuated serotype 1 virus (Rispen's strain) is used as a vaccine.





# Incubation Period

Natural Infection •

4-12 weeks •

Artificially Induced •

2-3 weeks •



# Course of Disease

**10-12 weeks**

**mortality will usually continue for life of the flock**

## • **Method of Spread**

1-This virus is shed via feather follicle epithelium, dander (small scales from feathers which flake off and can become airborne), secretions and excretions, so its spread by contaminated litter, dust, or air-borne (bird to bird). Feather (dust or dander) epithelium contains virus

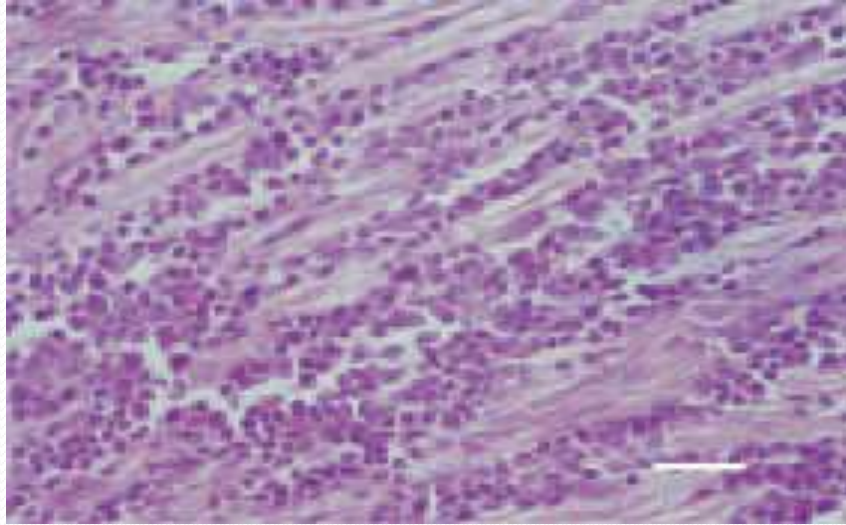
2-Air currents play a major role in the dissemination

3-Carrier states – produces latent infections

4-Also some Beetles considered as mechanical vectors

5-Vertical transmission is not considered to be important.

6- The virus may also be present in faeces and saliva. When cell-associated, the virus may survive for months in poultry house litter or dust and is resistant to some disinfectants.



Peripheral Nerve. A-Type Lesion (Neoplastic Type), Marked Lymphoid Cell Proliferation, Absence Of Oedema.



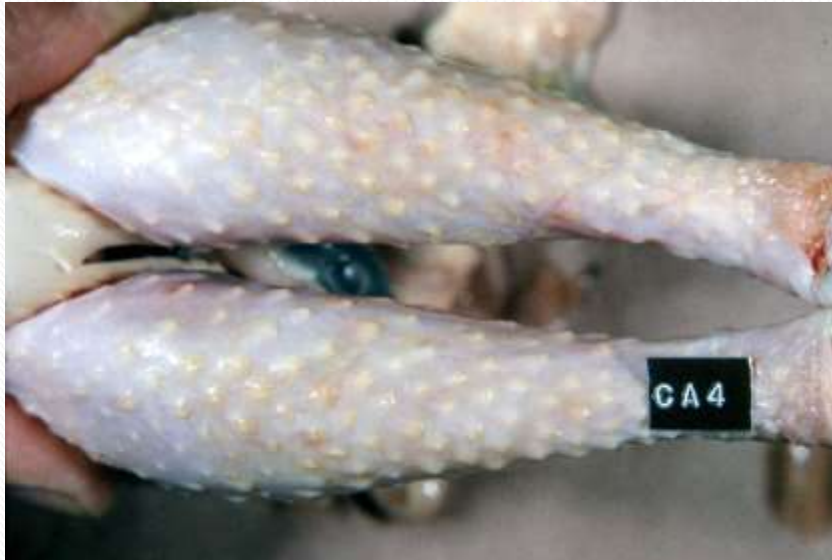
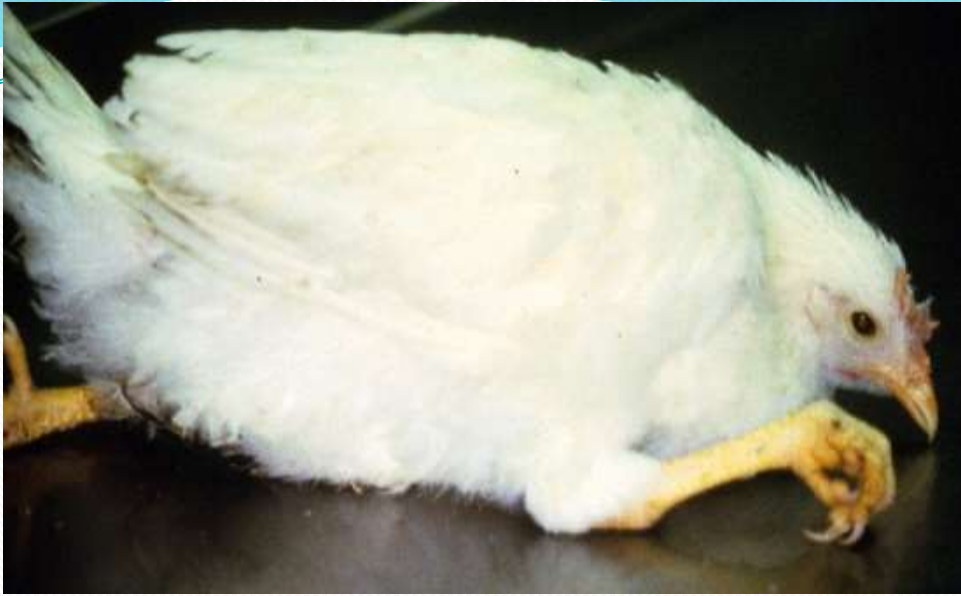
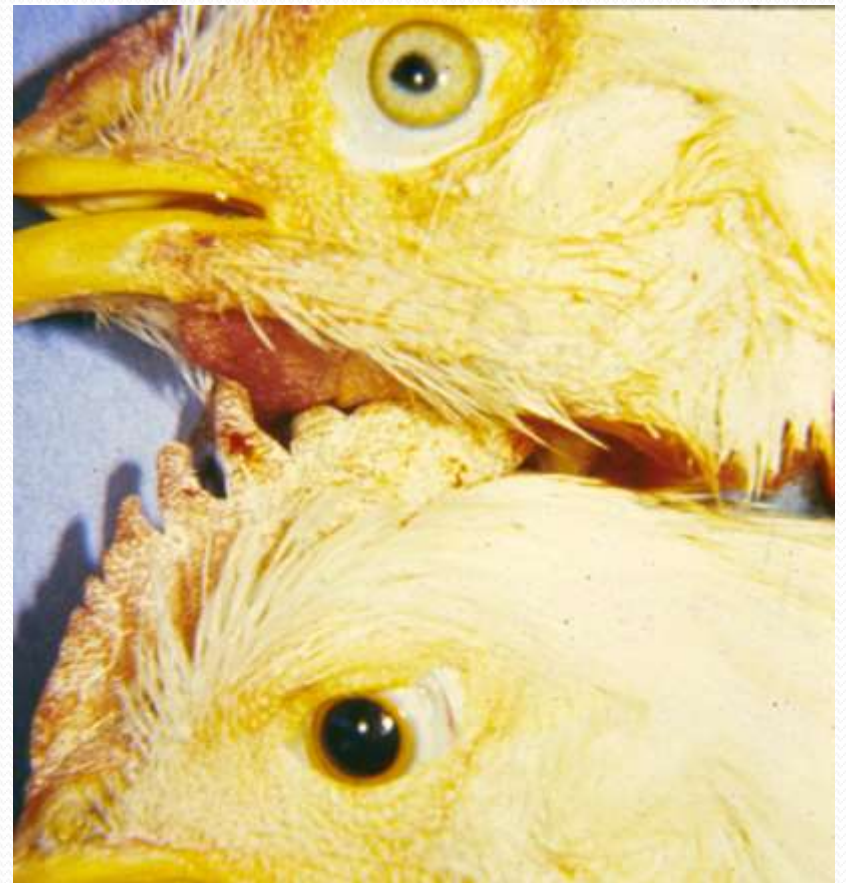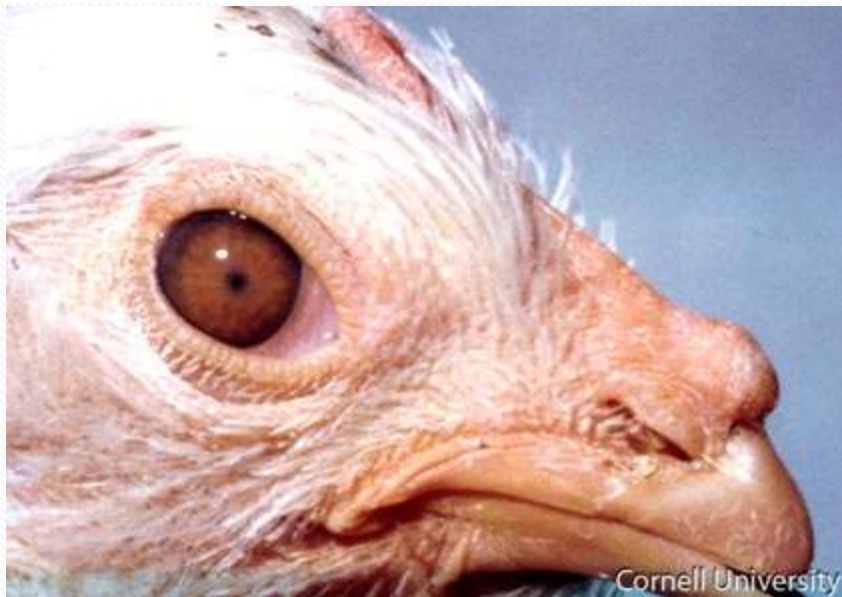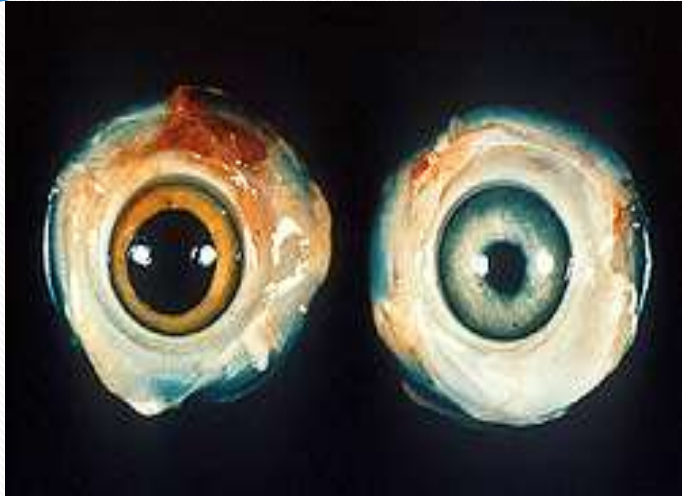
- **Mortality**

- Mortality generally only occurs in unvaccinated birds.
- In hens laying eggs, the mortality pattern will follow the egg production curve, due to the stress of egg production.
- Problems are worse in housing with poor airflow

## Clinical signs

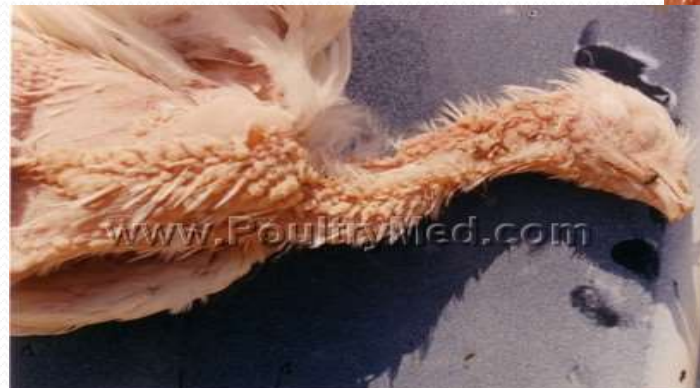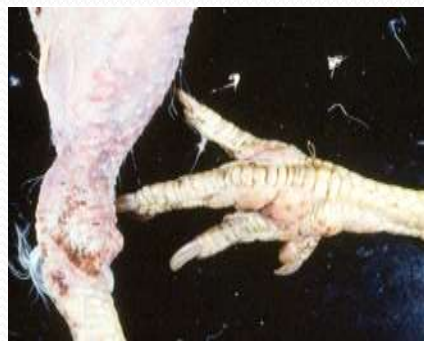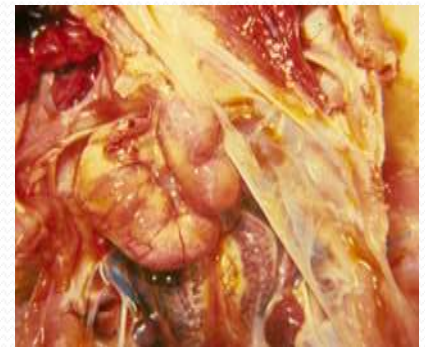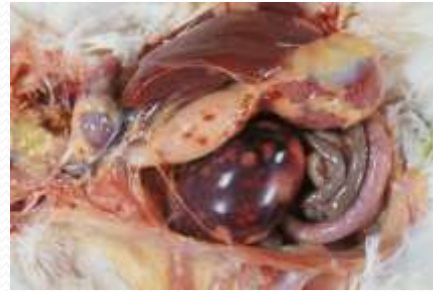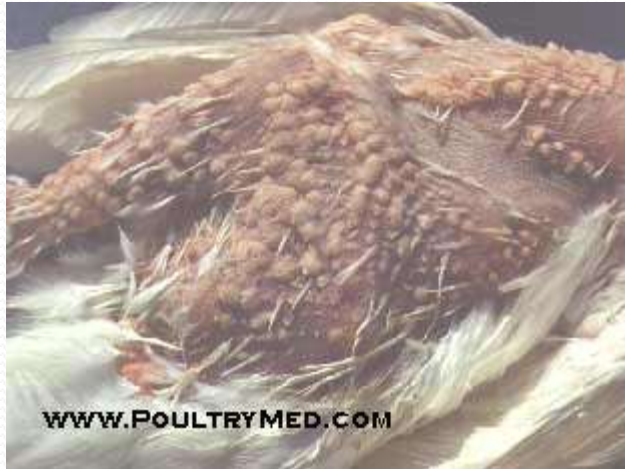- 1-Affected birds are immunosuppressed and as a consequence are more susceptible to other infectious diseases.
- 2- There can be unilateral or bilateral paralysis of wings and legs—and neck.
- 3-Loss of weight and Emaciated.
- 4- Grey iris or irregular pupil and decreases in size.
- 5-Skin around feather follicles raised and roughened.
- 6-Depression, anorexia and diarrhea
- 7-Pale shriveled combs

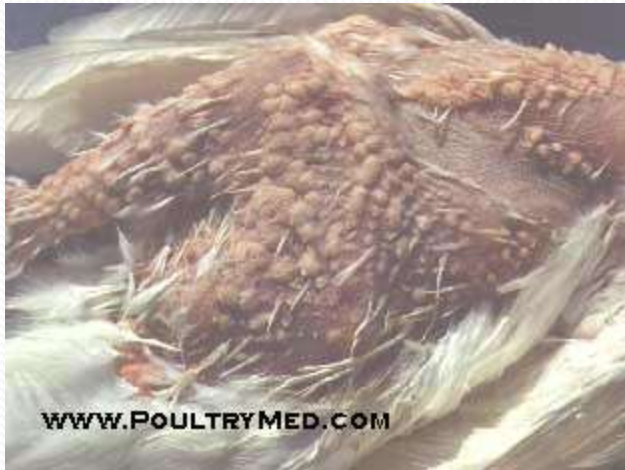
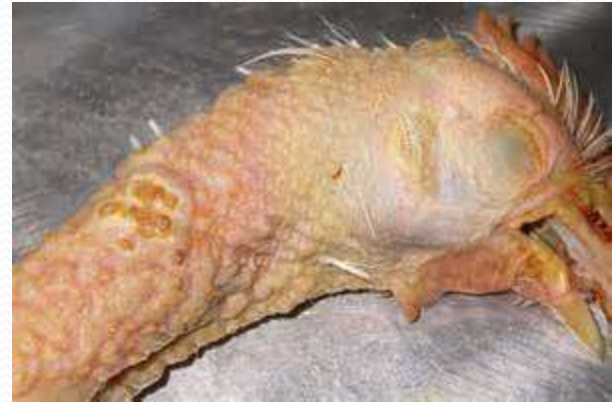
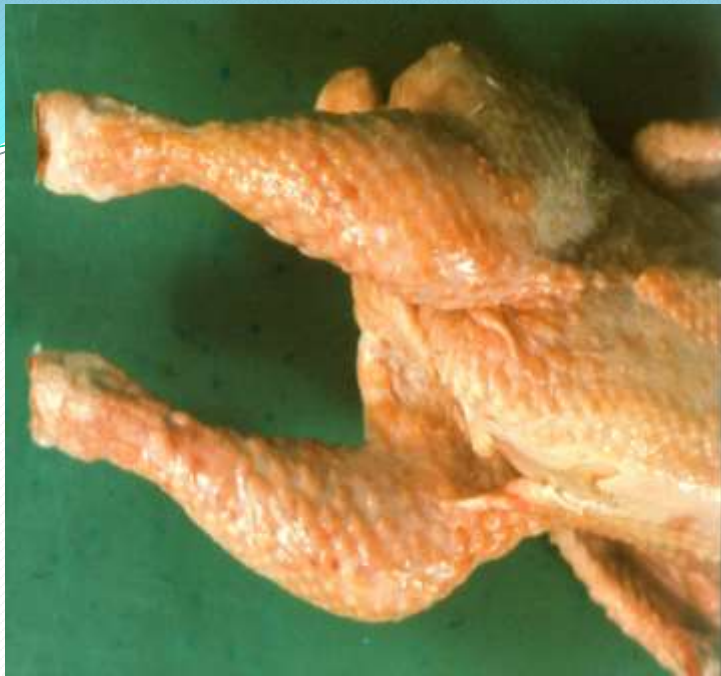

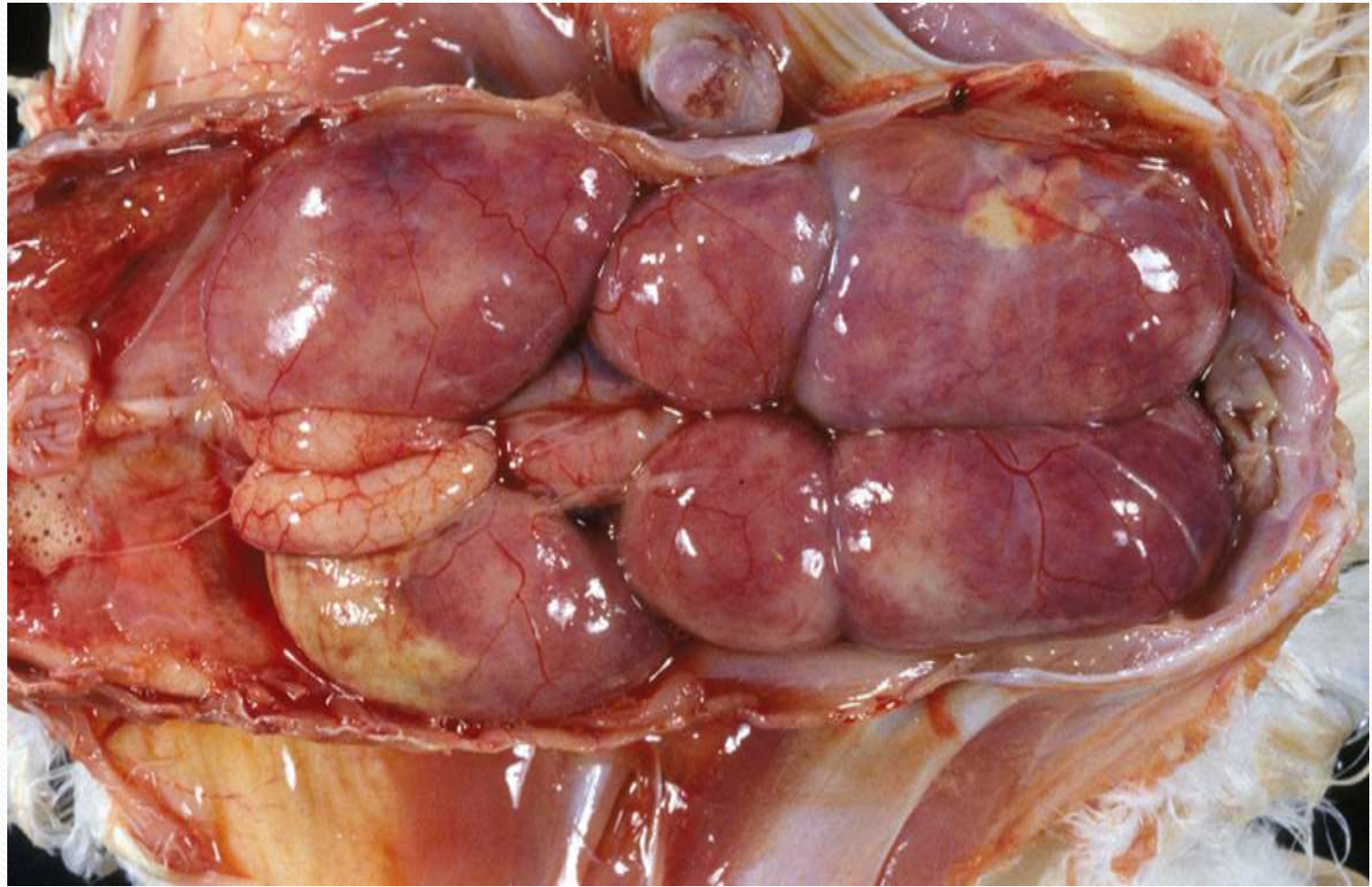
## ● **Postmortem Lesions**

- Feather follicles enlarged
- Grey-white foci of neoplastic tissue in liver, spleen, kidney, lung, gonads, heart, and skeletal muscle.
- Tumors on any or all visceral organs (some tumors may regress with time)
- Enlarged edematous nerves
- Nerve lesions can be seen as grayish, edematous, two or three times the normal thickness, and loss of the normal striated white glistening appearance.
- Nerves commonly affected include the brachial and sciatic plexi, celiac plexus, abdominal vagus and intercostals nerves.
- Many viremic birds die without showing any visible lesions



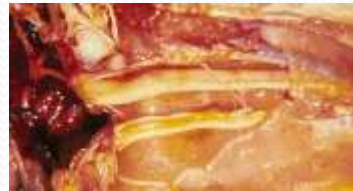
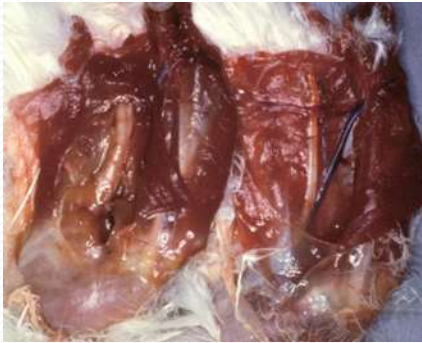
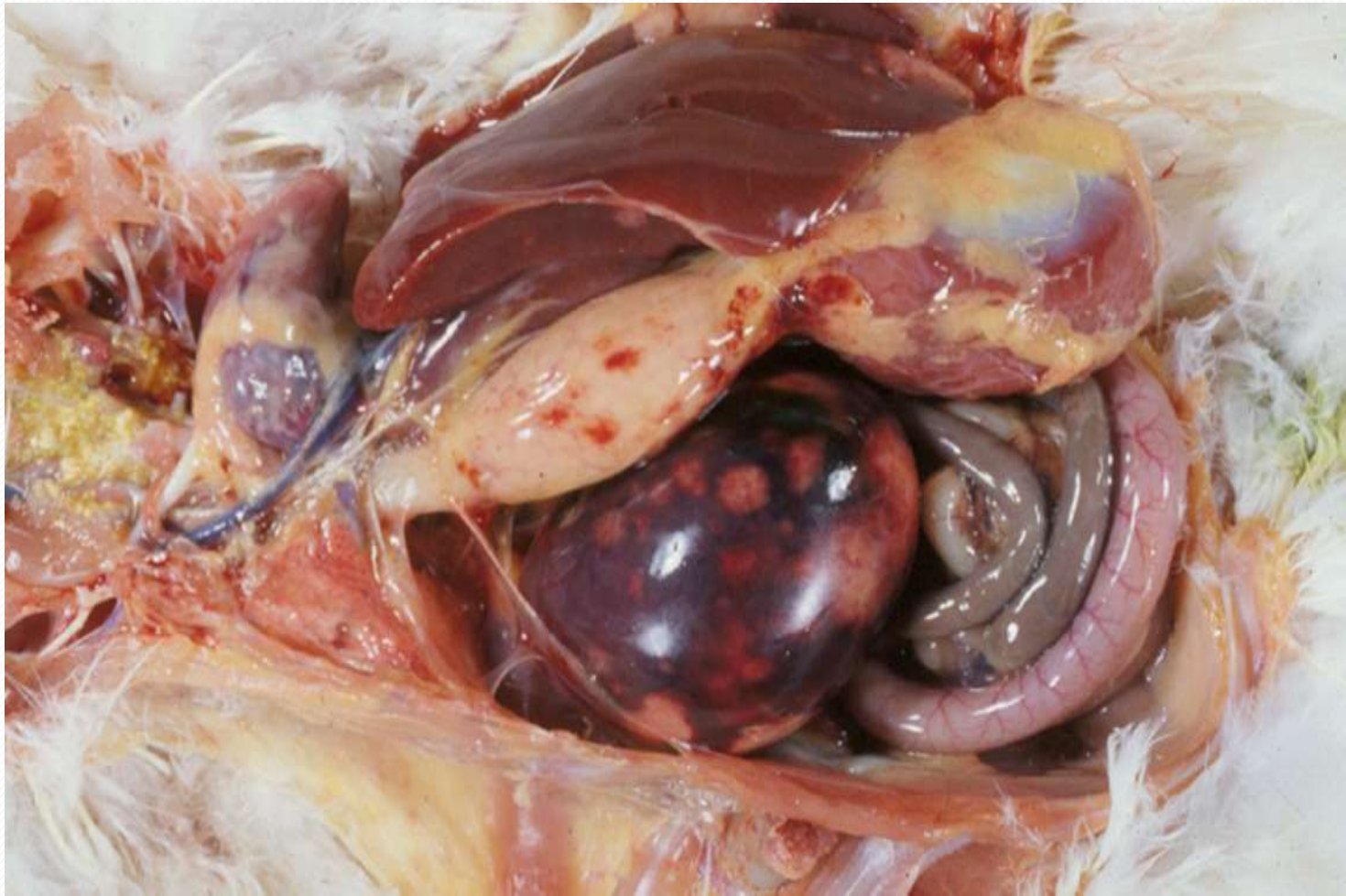
[WWW.POULTRYMED.COM](http://WWW.POULTRYMED.COM)

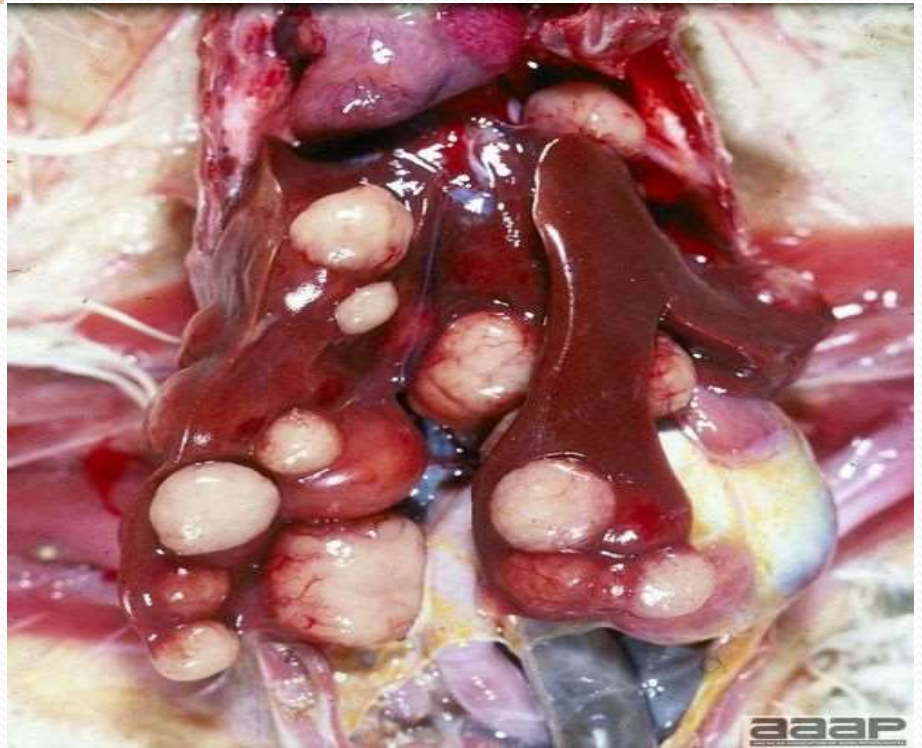
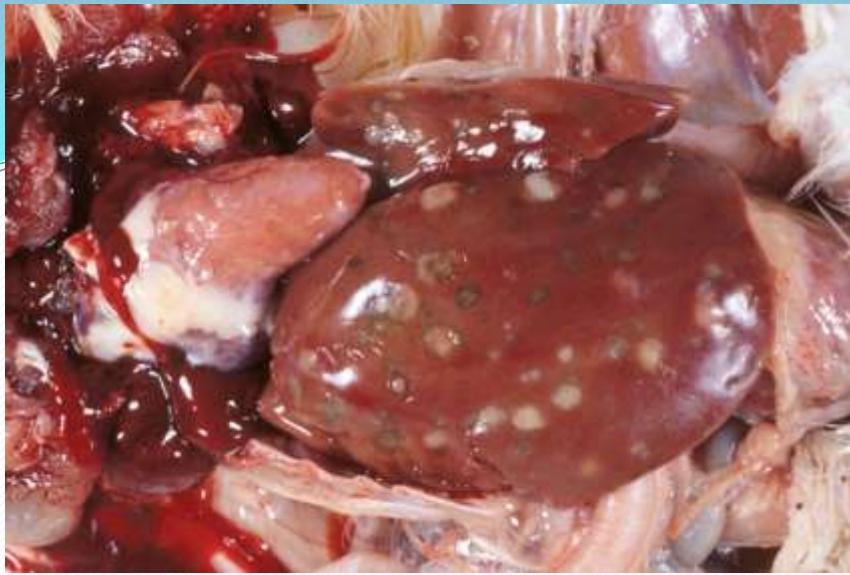


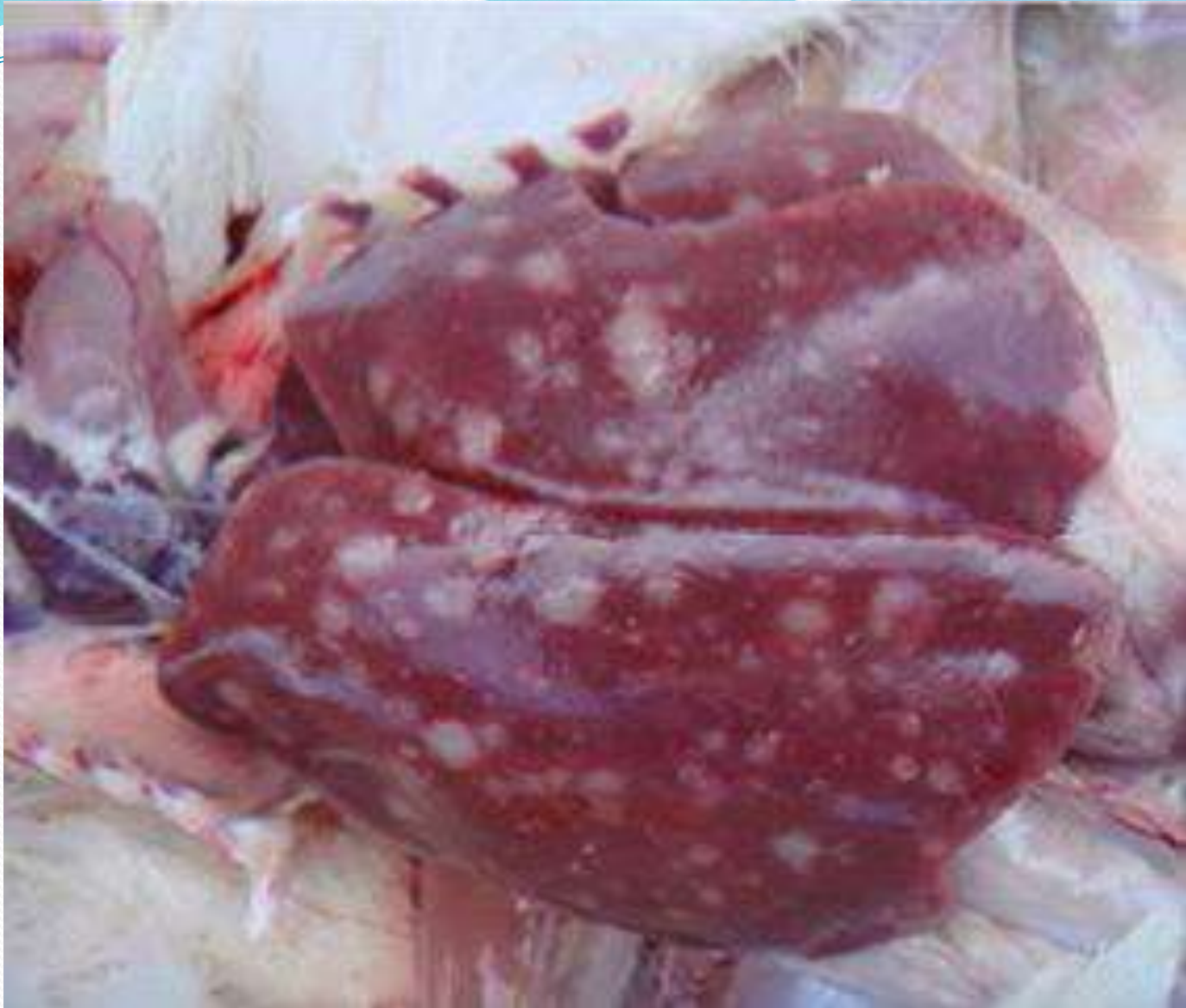

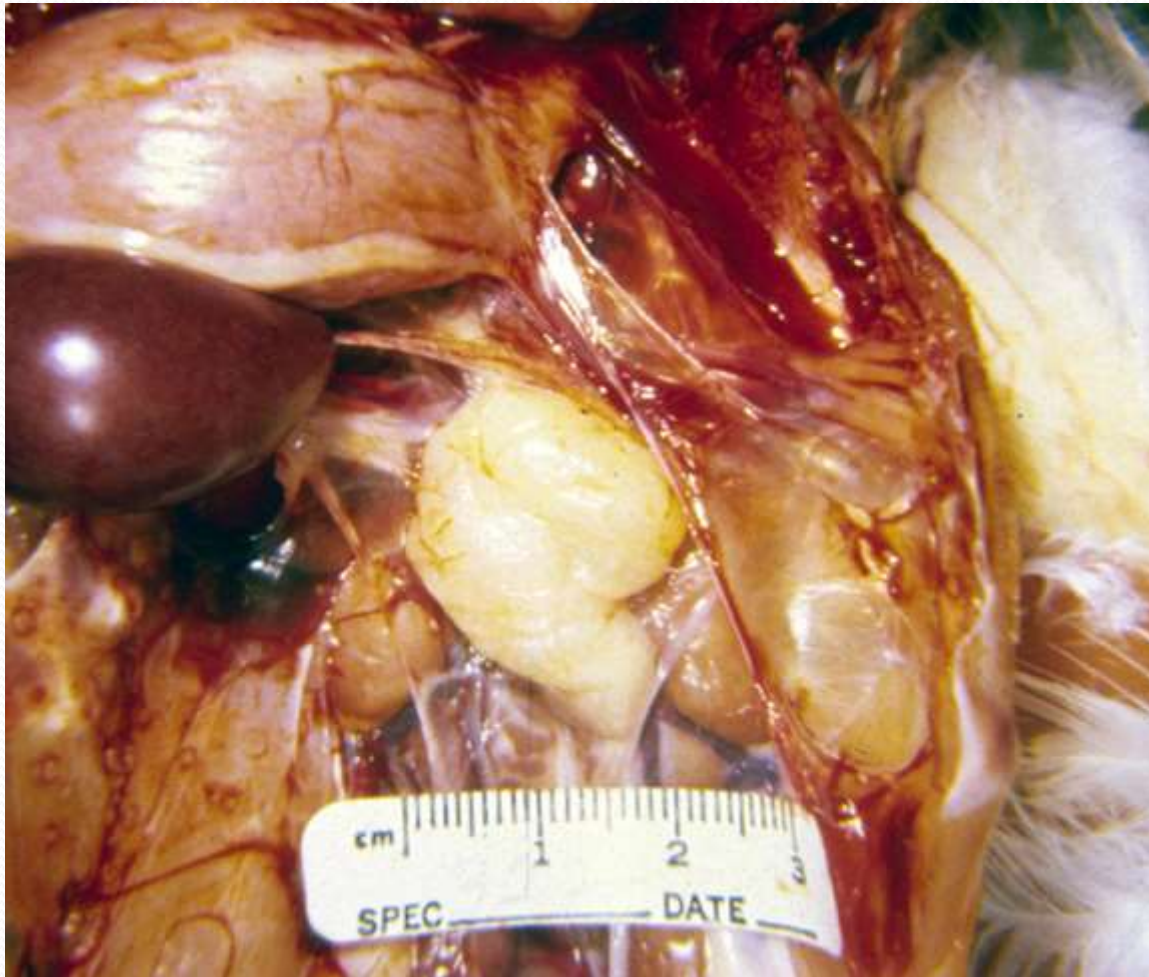# Affected/Normal Nerves

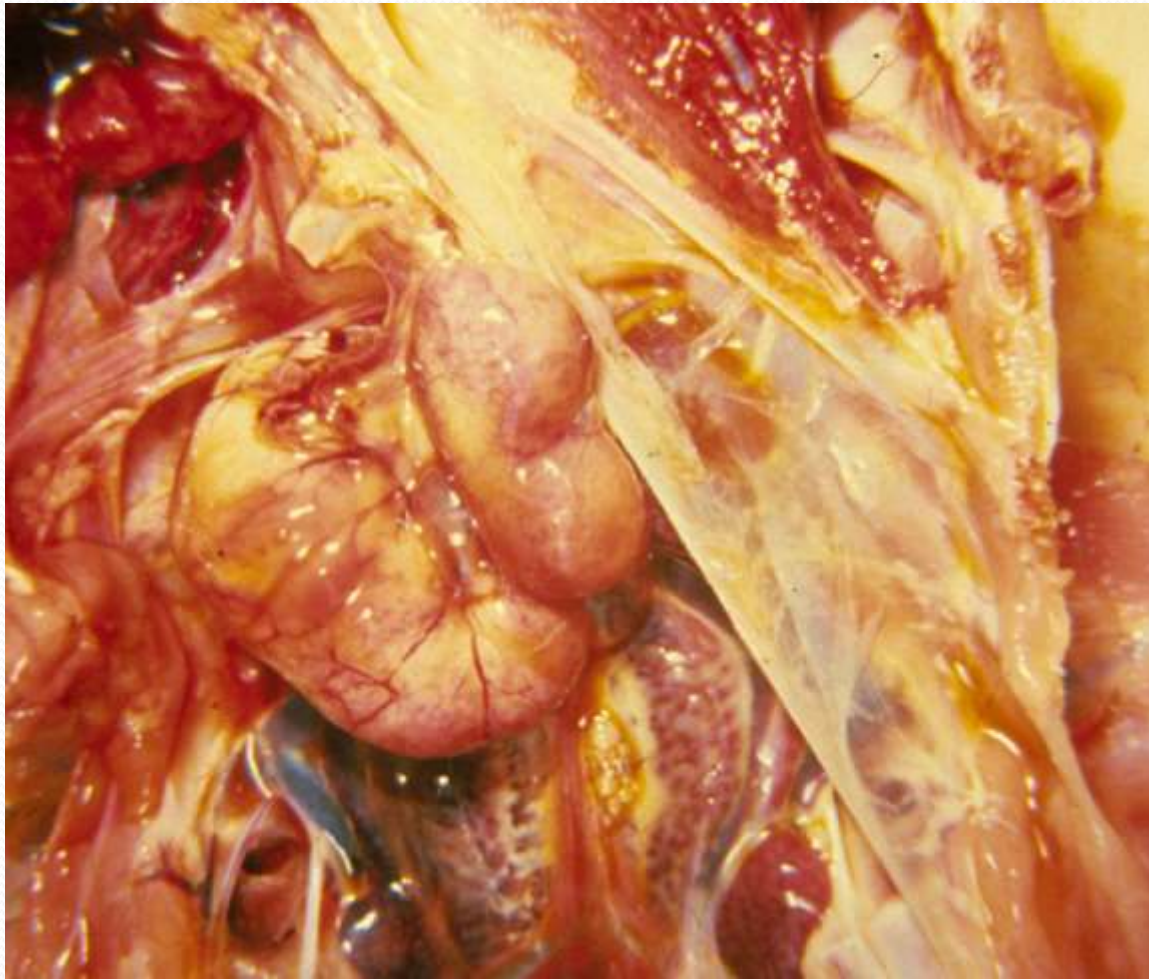

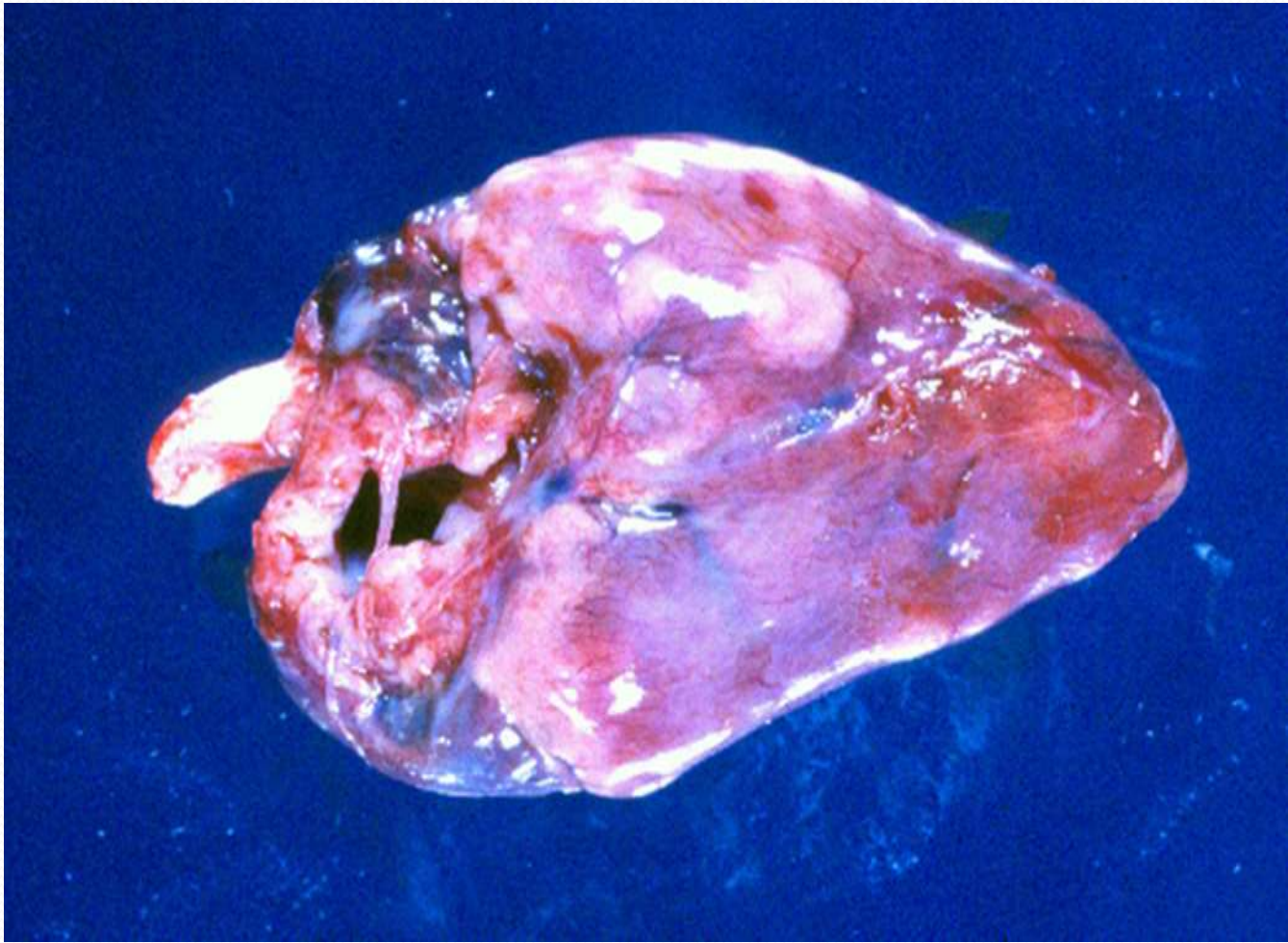


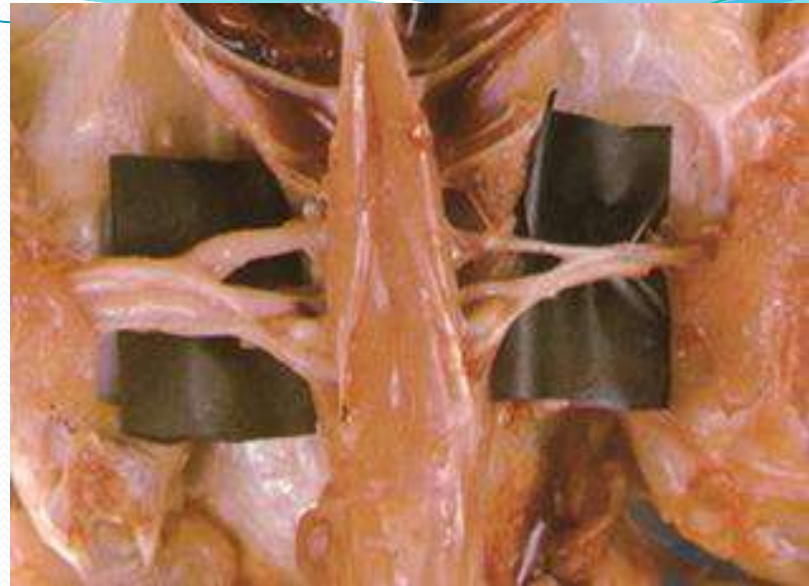




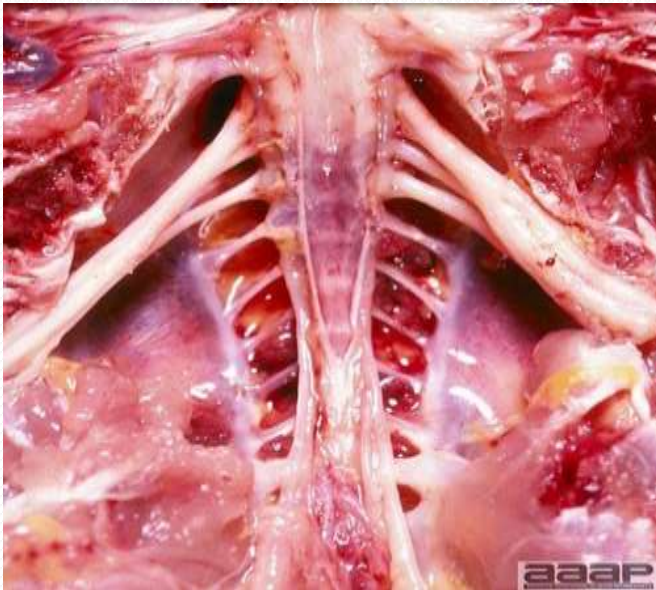






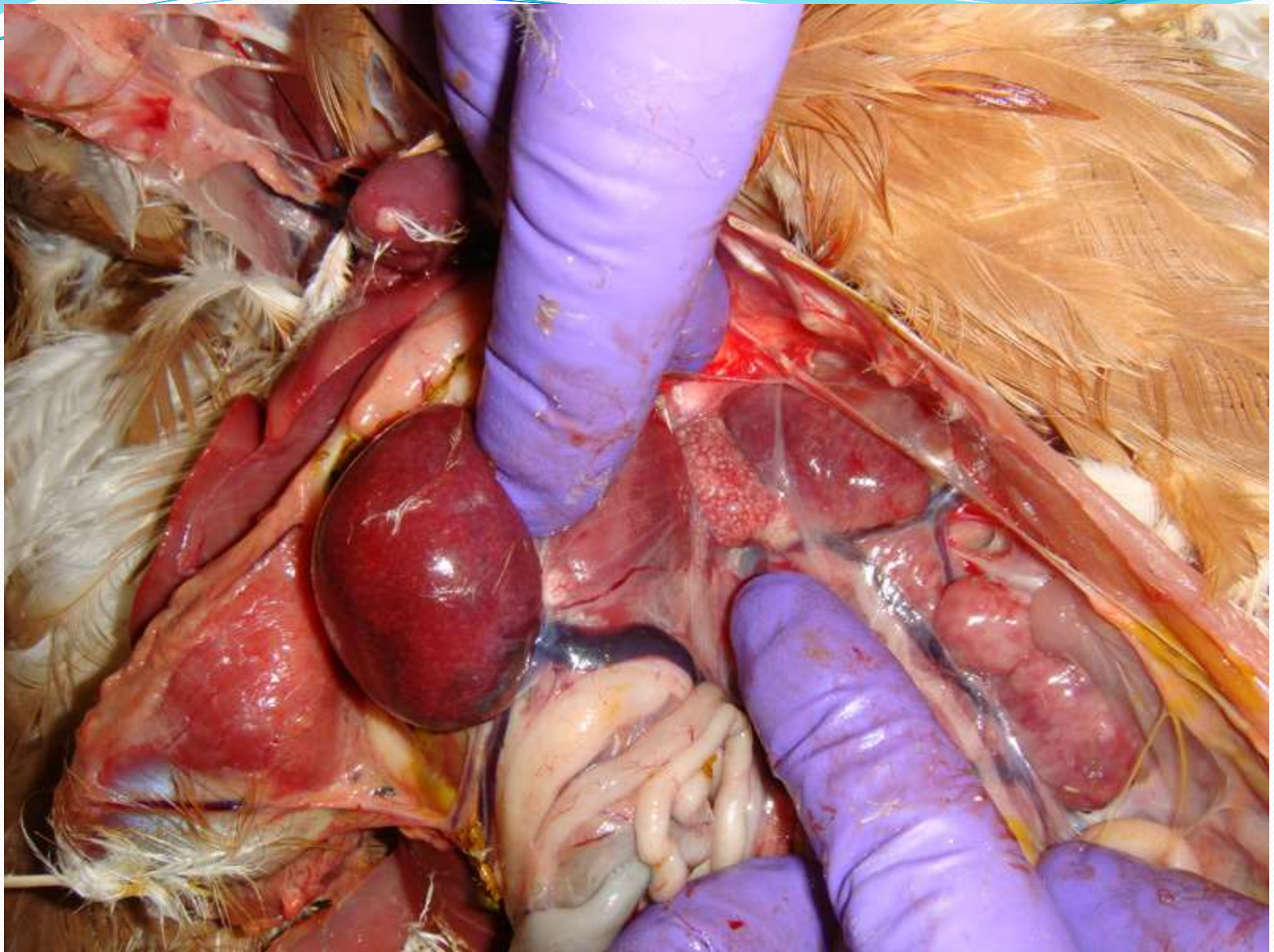


Sciatic nerves inflammation

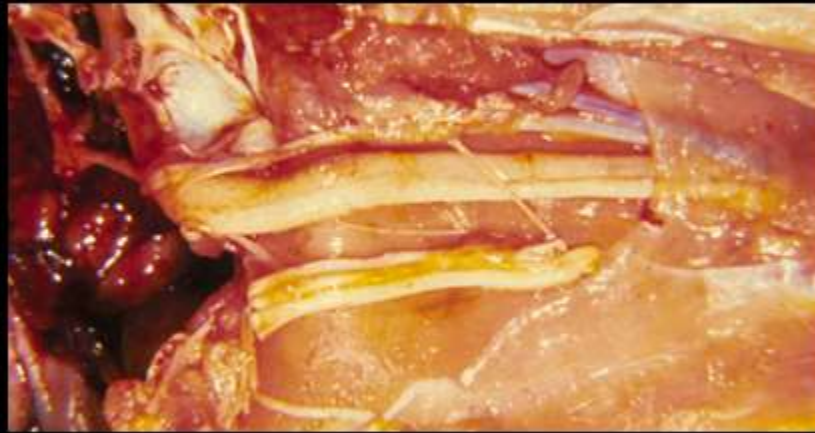


brachial nerve inflammation





## Affected/Normal Nerves



## ● **Diagnosis**

- A step-wise process has been proposed for diagnosis of Marek's disease which includes:
  - (1) history, epidemiology, clinical observations and gross necropsy,
  - (2) characteristics of the tumor cell, and
  - (3) virological characteristics which included isolation and characterization of the virus.
- Postmortem lesions: The demonstration of peripheral nerve enlargement along with suggestive clinical signs in a bird that is around three to four months old (with or without visceral tumors) is highly suggestive of Marek's disease.
- Histological examination of nerves reveals infiltration of pleomorphic neoplastic and inflammatory lymphocytes.
- Also histopathology – brain, nerve, spleen, liver, kidney, heart, bursa, skin – lymphocytic infiltration



- **Differential Diagnosis**

1-Lymphoid leukosis – older birds only MDV more common in younger birds

2-Riboflavin deficiency – causes hind limb paralysis

3-Various types of chronic hepatitis

i.e. Blackhead

4-Any disease causing CNS signs – NDV, AI, Encephalomalacia, etc.

## **Differentiating Marek's disease from lymphoid leukosis**

- (1) Age: MD can affect birds at any age, including <16 weeks of age;
- (2) Clinical signs: Frequent wing and leg paralysis;
- (3) Incidence: >5% in unvaccinated flocks;
- (4) Potential nerve enlargement;
- (5) Interfollicular tumors in the bursa of Fabricius;
- (6) CNS involvement;
- (7) Lymphoid proliferation in skin and feather follicles;
- (8) Pleomorphic lymphoid cells in nerves and tumors;
- (9) T-cell lymphomas

## **Histopathology**

There are two main types of lesions in peripheral nerves. Type A is interpreted as neoplastic in character, consisting of masses of proliferating lymphoblastic cells. Sometimes, demyelination and proliferation of Schwann cells are seen with these lesions. Type B is inflammatory in nature and is characterized by diffuse infiltration of lymphocytes and plasma cells, edema, and sometimes demyelination and Schwann cell proliferation. Lymphomatous lesions in visceral organs are more uniformly proliferative in nature. Deposition and diffuse proliferation of small to medium lymphocytes, lymphoblasts, and primitive reticulum cells are seen. Plasma cells are rarely present.

Skin lesions are mostly inflammatory and can also be lymphomatous. Inflammatory cells are localized around the infected feather follicle. With small lesions, the integrity of the skin is maintained, but disruption of the epidermis leading to ulcer formation may occur with massive proliferation.

Herpesviruses replicate in the bursa of Fabricius and the thymus which results in degenerative changes in these organs. Atrophy of the thymus can be severe and involve the cortex and medulla. In some cases, lymphoid proliferation in the thymus was seen. Arterial lesions may occur in the aorta, coronary, celiac, gastric and mesenteric arteries which may show fatty proliferative changes.


## **Prevention and treatment of Marek's disease**

There is no treatment for MD. Vaccination is the central strategy for the prevention and control of MD. While vaccination will prevent clinical disease and reduce shedding of infective virus it will not prevent infection.

It was found that better protection from MD was obtained when certain combinations of serotypes were used together in a vaccine rather than one serotype alone (protective synergism).

This phenomena, which is unique to MD and is strongly serotype specific, has led to the development of polyvalent vaccines (vaccines containing more than one vaccine strain).





Vaccines administered at hatching require 1-2 weeks to produce an effective immunity, therefore exposure of chickens vaccinated at hatching to virus should be minimised during the first few days after hatching. Vaccines are also effective when administered to embryos at the 18th day of incubation.

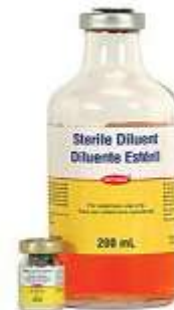In ovo vaccination (vaccination of the embryo prior to hatching) is now performed by automated technology and is widely used for vaccination of commercial broiler chickens, mainly because of reduced labour costs and greater precision of vaccine administration.

- Vaccination

- Probably the most widely used vaccine consists of turkey herpesvirus (HVT), which has seen rapidly increased use in recent years as a backbone in recombinant vaccines.

The vaccines given at day 1 by subcutaneous injection in the hatchery or in-ovo at transfer.

- The vaccine contains the FC-126 strain of turkey herpesvirus and the SB-I strain of chicken herpesvirus.
  - Modified Live Marek's Virus CVI-988/C - Rispen's chicken origin
    - Serotype III
    - Use Combined with HVT





QUALITY WASHER

